

ONLINE ONLY

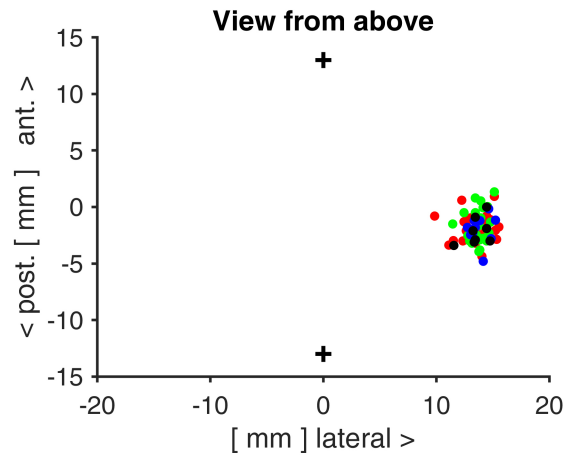
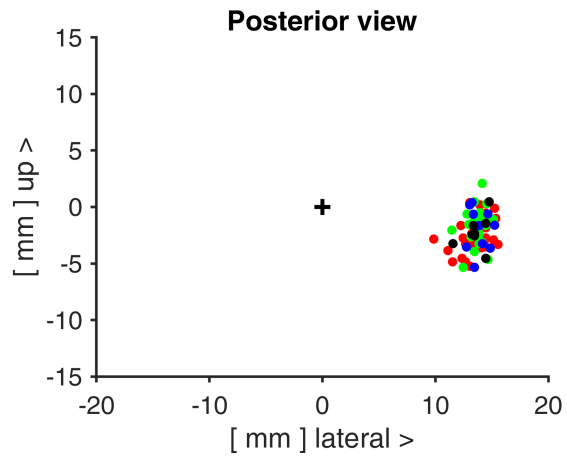
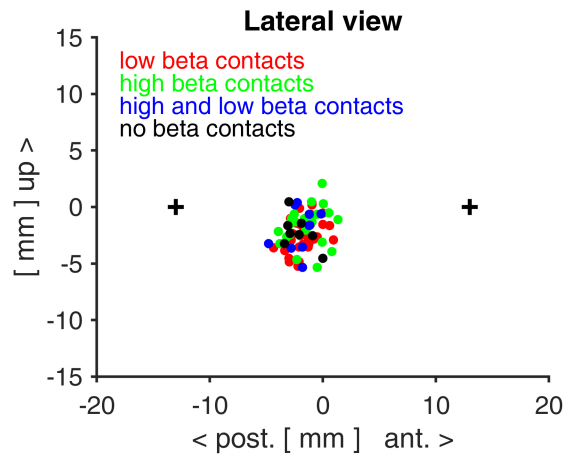
Supplemental material

Peaks in the beta band of the human subthalamic nucleus: a case for low beta and high beta activity

Plate et al.

<https://thejns.org/doi/abs/10.3171/2021.3.JNS204113>

DISCLAIMER The *Journal of Neurosurgery* acknowledges that the following section is published verbatim as submitted by the authors and did not go through either the *Journal's* peer-review or editing process.



Supplemental Figure 1

Position of recording sites within the AC-PC coordinate system. AC and PC are marked (+).

Recording sites were grouped according to whether they displayed low beta, high beta, both or no beta.

These locations are shown in different colors. A spatial collocation of the different recording sites is not visible.