

ONLINE ONLY

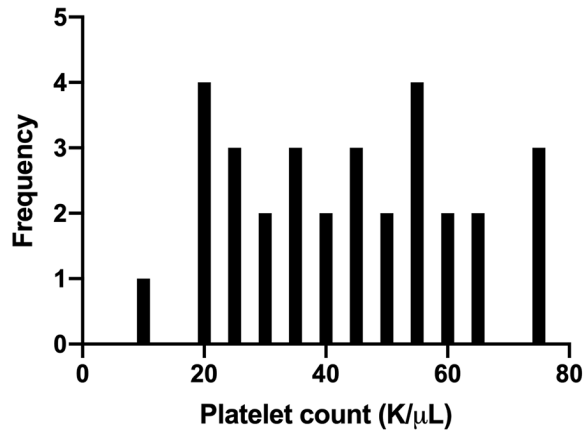
## Supplemental material

**Middle meningeal artery embolization for chronic subdural hematoma in cancer patients with refractory thrombocytopenia**

Lee et al.

<https://thejns.org/doi/abs/InsertDOIfromJPS>

**DISCLAIMER** The *Journal of Neurosurgery* acknowledges that the following section is published verbatim as submitted by the authors and did not go through either the *Journal's* peer-review or editing process.



Supplementary Figure 1. Histogram of platelet counts.